PCIPEDIA.ORG
part of cardionetworks.org

INDICATIONS CORONARY ANGIOGRAPHY (CAG)

Class I: STEMI: Acute, NSTEMI: 24-72 hours (timing based on GRACE score).
Class I: Disabling stable angina pectoris (CCS III-IV) despite medical therapy, high-risk criteria on clinical assessment / noninvasive testing, unexplained heart failure, survivors of cardiac arrest, severe ventricular arrhythmias, angina in conjunction with signs of heart failure, heart failure eci, early recurrence of angina after PCI/ CABG, or pre cardiac valve surgery (♂: >35 yrs, ♀: >50 yrs.).
Class IIa: Inconclusive or conflicting results after noninvasive stress testing, unable to undergo noninvasive testing (disability, illness, or morbid obesity), reevaluation of performed procedures (main stem PCI, high restenosis risk).
Class III: Risk of CAG outweighs the benefit (significant comorbidity) or mild angina (CCS class I or II) responding well to medical therapy. **Always use common sense!**

EFFICIENT CAG

Systemic evaluation of the coronary tree: → do not miss any occluded vessel or anomaly.

- Coronary lesions often have an eccentric appearance → make several orthogonal projections to be sure you do not miss an eccentric stenosis (see figure).
- Be sensitive to catheter wedging, ostial lesions, catheter induced coronary spasm and over projection of tortuous vessels.
- Assess projections with a meaning:

RCA: Proximal: **L 45** (15-50), **Cranial** 0 (0-35)
Mid: **L 45, R30** (0-45)
Crux: **L 25** (15-50), **Cranial 25** (0-35)
LCA: Main stem: **R0** (0-10), **Cranial 0** (-40 to +40)
LAD proximal: **R5** (5-45), **Cranial 35** (Caudal -40 to +40)
LAD mid / distal: **R 30** (-50-30), **Cranial 30** (0-40)
RCx proximal: **L45** (-5-50), **Caudal 30** (20-40)
RCx: OM mid -distal: **L45** (-5-50), **Caudal 35** (-30-40)
LV angio: **R** 30-0, **L** 45-0
Aorta angio: **R** 20-0, **L** 45-0

RIGHT CARDIAC CATHETERIZATION

Location	Pressure (mmHg)	Saturation
RA	a (2-10) , v (2-10)	75
RV	0-30	75
PAP	3-30	75
PCW	a (3-15) , v (3-12)	97
Cardiac Output (CO)	3-6 l/min	
Cardiac Index (CI)	2.5-3.5 l/min	
Pulmonary Vascular Resistence (PVR)	20-130 dynes • sec • cm^{-5} (PAP-PCW)/CO	
Systemic Vascular Resistence (SVR)	700-1600 dynes • sec • cm^{-5} (P_{aorta}-RAP)/CO	

(RELATIVE) CONTRA-INDICATIONS FOR CAG

Symptomatic heart failure, uncontrolled hypertension, refractory arrhythmia, severe contrast medium allergy, inability for patient cooperation, pregnancy, active infection, severe renal failure, coagulopathy / anticoagulant state (high INR / PT), severe hemorrhage, intoxication (digitalis), or electrolyte disturbance (hypokaliema).

INTRACORONARY PARAMETERS OF STENOSIS SEVERITY

While coronary angiography is used as the gold standard for documentation of the presence and extent of coronary artery disease, it has its limitations in assessing the functional significance of coronary stenoses and particularly in intermediate coronary lesions, i.e. lesions with diameter stenosis 40-70%. Therefore, intracoronary derived pressure, flow and intravascular ultrasound (IVUS) parameters have been validated for clinical decision making in the cathlab (see Table below). Ischemia and defer values for IVUS are: lumen cross sectional area of >3.0-4.0 mm^2 in a coronary artery and >6,0 mm^2 for the mainstem (MS).

	FFR	iFR	CFR	HSR
Normal Value	1.0	1.0	> 3.0	0
Ischemia detection	< 0.75	0.90	< 2.0	> 0.80
Defer PCI	> 0.80	na	> 2.0	na
Defer PCI ACS	> 0.80	na	na	na
Defer PCI MS	> 0.80	na	na	na

FFR: fractional flow reserve; iFR: instantaneous wave-free ratio; CFR: coronary flow (velocity) reserve; HSR: hyperemic stenosis resistance (mmHg • cm^{-1} • s^{-1}).

BLOOD SUPPLY CARDIAC CONDUCTION SYSTEM

SA node: RCA in 55-60 %
AV node: RCA in 90 %
His bundle : RCA / LAD
Right bundle (RBB): LAD (S1)
Left bundle (LBB):
• Anticus (AF): LAD
• Posticus (PF): LAD/ RCA

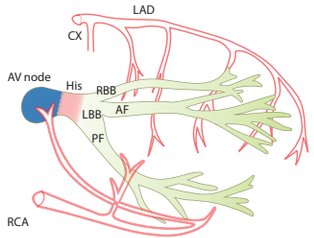

NOMENCLATURE PCI SEGMENTS

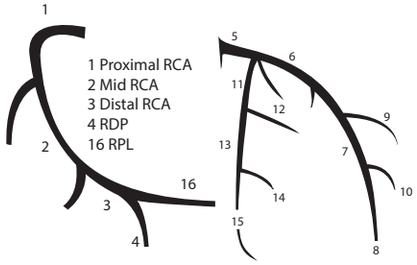

RIGHT CORONARY ARTERY (RCA):

Left Anterior Oblique View (L45-0)
Use: Catheter intubation, Optimal visualisation:
RCA- proximal, -mid and -distal

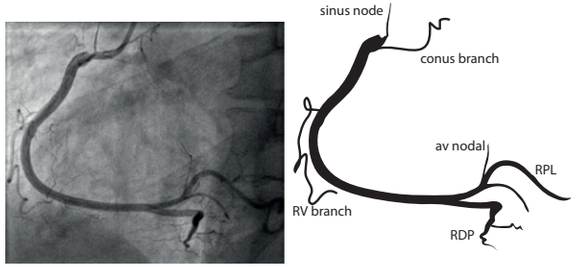

RIGHT CORONARY ARTERY (RCA):

Left Anterior Oblique and Cranial View (L20-C25)
Optimal visualisation: RCA-proximal, -distal, -crux, RDP, RPL

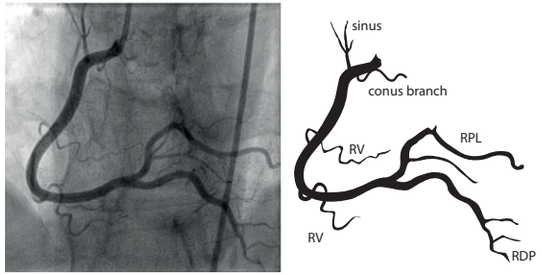

RIGHT CORONARY ARTERY (RCA):

Right Anterior Oblique View (R30-0)
Optimal visualisation: RCA-mid collateral vessels to LAD (if present)

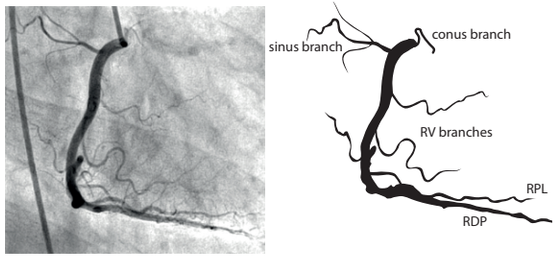

LEFT CORONARY ARTERY (LCA):

Left Anterior Oblique and Cranial View (L50-C20)
Optimal visualisation: Mainstem ostium, LAD-mid-distal, Diagonals, RCX-mid-distal

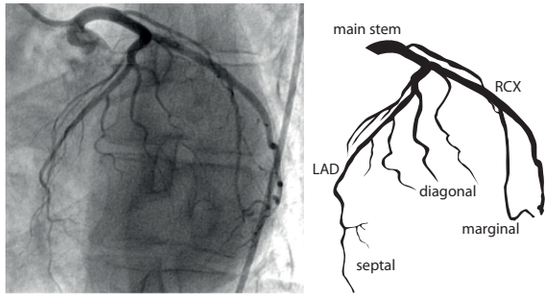

LEFT CORONARY ARTERY (LCA):

Left Anterior Oblique and Caudal View (Spider; L50-C25)
Optimal visualisation: Mainstem ostium-body-bifurcation, LAD-proximal, RCx-proximal-mid

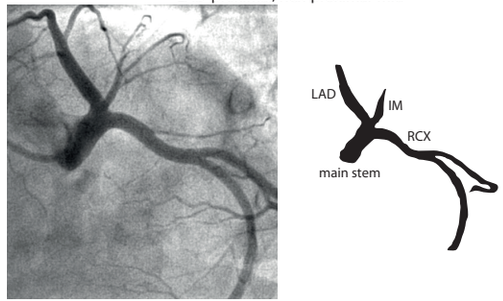

LEFT CORONARY ARTERY (LCA):

Right Anterior Oblique View (R30-0)
Optimal visualisation: Mainstem body, LAD-mid-distal, MO

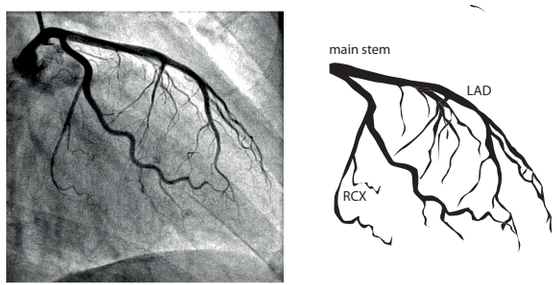

MODEL OF CORONARY ARTERIES IN ATRIOVENTRICULAR AND INTERVENTRICULAR PLANES

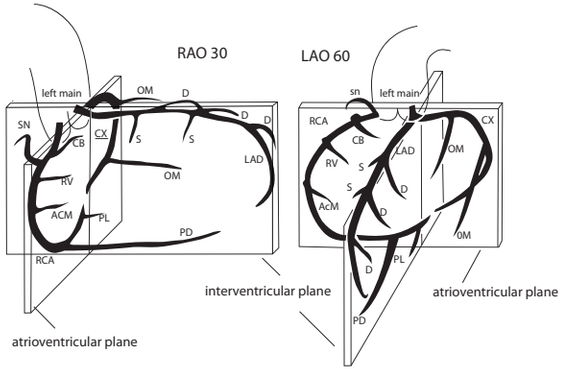

LEFT CORONARY ARTERY (LCA):

Left lateral view (L90-0)
Optimal visualisation: LAD-mid-distal, LIMA anastomosis (if present), RCx-mid-distal

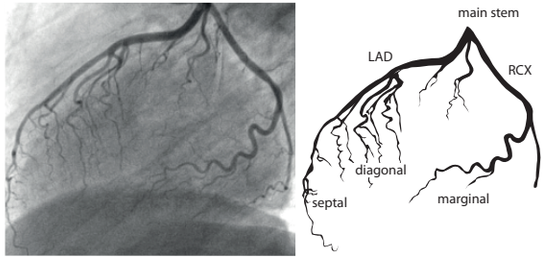

LEFT CORONARY ARTERY (LCA):

Right Cranial View (R5-C40)
Optimal visualisation: LAD-proximal-mid-distal, LIMA anastomosis (if present), Diagonals

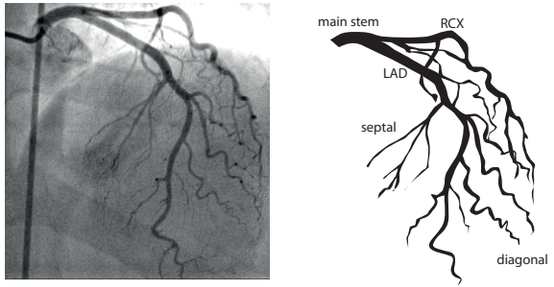

LEFT CORONARY ARTERY (LCA):

Right Caudal View (R5-C40)
Optimal visualisation: MS-bifurcation, LAD-proximal, RCx-proximal-mid-distal, MO-bifurcation

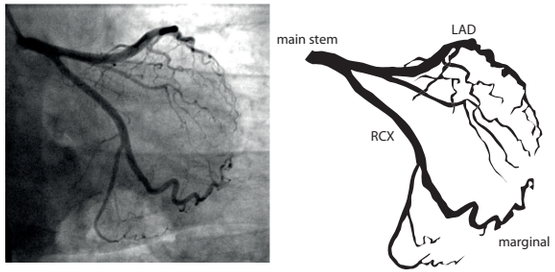

OVERVIEW OF CORONARY VESSELS INCLUDING LEFT AND RIGHT DOMINANCE

- In 85% of patients, the coronary circulation is right dominant: RCA → crux → RPL and RDP.
- In 10% of patients, the coronary circulation is left dominant: RCA → RPL and no RDP (LCA).
- In 5% of patients, the coronary circulation is balanced: RCA RDP and no RPL (LCA).

ECG in RCA occlusion: ST elevation III > II, ST depression in aVL > I , V4R isoelectric or elevated S:R in aVL > 3.
ECG in RCX occlusion: ST elevation II > III, V4R negative T, S:R in aVL < 3.
ECG in Anterior infarction:

Main stem	LAD, proximal to S1 / D1:	LAD, distal to S1 / D1:
1) ST ↑ vector -90 º 2) ST ↑ in aVR > V1 3) ST ↑ in V1-2 4) ST ↑ V1 ≥ 2,5 mm 5) RBBB, Left axis 6) ST ↓ II ≥ 1,0 mm 7) ST ↓ max in V5-6	1) See mainstem nr. 2-7 2) ST vector -90 º and -30 º 3) ST ↑ V1-6 4) ST ↓ II, III, aVF	1) ST vector: 0 º - 90 º 2) ST ↑ V1-6, II - aVL 3) No ST ↓ III 4) ST ↓ II, III, aVF